



**PATIENT**  
Anuja Renaud-Ingel

**SPECIES**  
Feline

**BREED**  
DMH

**SEX**  
Female Spayed

**AGE**  
11 years

**WEIGHT**  
12.3lbs

**INTERPRETED BY**  
Maggie Machen  
Lamy, DVM  
DACVIM (Cardiology)

**IMAGING PERFORMED BY**  
Pamela Harrigan,  
RDCS

**HOSPITAL NAME**  
Mass Veterinary Services

**REFERRING VET**  
Dr. Masloski

**INVOICE**  
25028

**DATE**  
6/28/22

**PRESENTING CLINICAL SIGNS**

History: Recheck echo. History HCM with focal asymmetric hypertrophy and endocardial fibrosis; borderline LAE. Currently, Anuja is doing well clinically with a good appetite and activity level. On exam today: gallop, grade III/VI murmur with PMI on sternum, PSS, lung fields clear, compressible thorax. BP: 130mmHg x 4. No cardiac medications. \*No sedation for study  
-Pertinent previous measurements: LA 1.4 cm; LA:Ao 1.4; IVS 0.66 cm; PW 0.49 cm.

**ECHOCARDIOGRAM FINDINGS**

2D, m-mode, color flow and Doppler imaging is available.  
**Left ventricle:** The LV diameter is normal with adequate myocardial function. The LV wall thicknesses are asymmetric with mild septal thickening. There is a diffusely hyperechoic endocardium consistent with fibrosis. The papillary muscles are asymmetrically hypertrophied with a fused morphology.  
**Left atrium:** The left atrium is mildly enlarged. No obvious spontaneous contrast or thrombi seen.  
**Mitral valve:** The mitral valve is normal in structure and mobility. No obvious systolic anterior motion is seen. Trace MR.  
**Aortic valve/Aorta:** The aortic valve is mildly thickened. Normal aortic outflow velocity; laminar flow. No aortic insufficiency.  
**Right ventricle:** Normal right ventricular diameter and morphology indicating no overt evidence of pulmonary arterial hypertension.  
**Right atrium:** The right atrium is normal in dimension.  
**Tricuspid valve:** The tricuspid valve appears normal with no tricuspid regurgitation.  
**Pulmonic valve/Pulmonary artery:** The pulmonic valve is normal in morphology and mobility. No pulmonic insufficiency. Normal RVOT velocity; laminar flow.  
**Pericardium/other:** No pericardial or pleural effusion noted. No obvious cardiac masses.  
**Heart rhythm:** ECG reveals a sinus rhythm with an average HR of 200bpm.

**2-Dimensional Measurements**

Ao diam (cm)	1.0
LA diam (cm)	1.5
LA:Ao (Swe)	1.5
IVS thickness (cm)	0.62
LVID diastole (cm)	1.7
PW thickness (cm)	0.55
LVID systole (cm)	0.94
FS (%)	47

**Doppler Measurements**

PV Vmax (m/s)	0.9
AoV Vmax (m/s)	1.3
MR Vmax (m/s)	NA
TR Vmax (m/s)	NA
TR PG (mmHg)	NA

**INTERPRETATION OF THE FINDINGS**

HCM persists with mild septal thickening. Findings are similar to the previous study without evidence of progression. Mild LA enlargement indicates the risk is persistently low for complication.

Prognosis is guarded long-term, due to the highly variable rates of progression with subclinical feline cardiomyopathy.



**PATIENT**

Anuja Renaud-Ingel

**SPECIES**

Feline

**BREED**

DMH

**SEX**

Female Spayed

**AGE**

11 years

**WEIGHT**

12.3lbs

**INTERPRETED BY**

Maggie Machen Lamy, DVM  
DACVIM (Cardiology)

**IMAGING PERFORMED BY**

Pamela Harrigan, RDCS

**HOSPITAL NAME**

Mass Veterinary Services

**REFERRING VET**

Dr. Masloski

**INVOICE**

25028

**DATE**

6/28/22

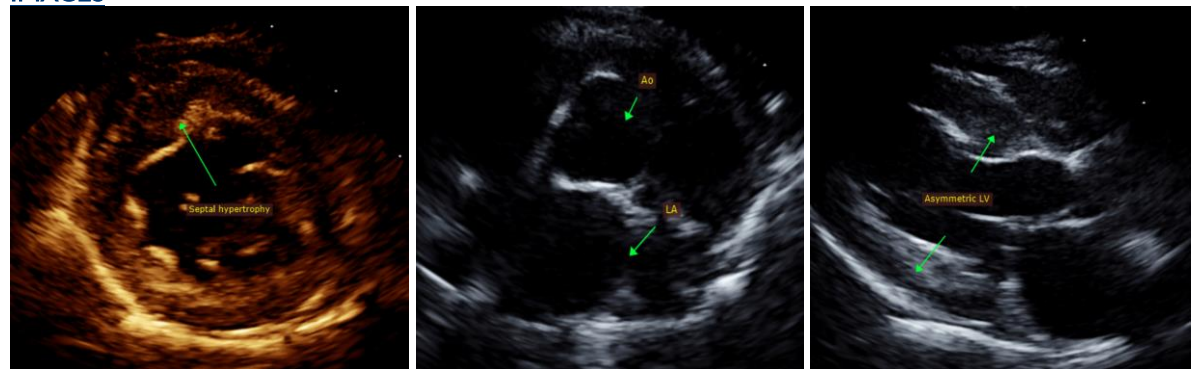
**RECOMMENDATIONS**

- Given these findings, no medications are indicated.
- Monitor BP and T4 every 6 months.
- Anesthetic risk is considered mild, however judicious IV fluid rates are advised to avoid fluid overload. Additionally, drugs that stimulate heart rate should be avoided unless clinically necessary (glycopyrrolate, atropine). A reasonable protocol includes opioid/benzodiazepine premedication, propofol induction, isoflurane maintenance.
- Risk for complication with steroid use typically follows LA dilation, which in this case is low. That being said, any cat can experience unexpected signs of intolerance and monitoring of RR/RE is advised particularly in the initiation phase.
- Monitor for any clinical evidence of cardiac compromise, including respiratory changes and/or signs of a blood clot event (paralysis, neurologic changes, etc.).

**PLAN**

- Recommend recheck echocardiogram in 6-12 months to screen for progression, sooner if any clinical signs arise in the interim.

**IMAGES**



The information and recommendations provided are based on the images presented by the referring veterinarian. No evaluation can be communicated regarding pathology that was not visible in the image/video clips provided.

Thank you for this referral. This report was generated using transcription software, and minor dictation errors may be present. If the clinical or image interpretation does not parallel your findings or if I can be of any further assistance, please contact me.

Maggie Machen Lamy, DVM  
Diplomate of the American College of Veterinary Internal Medicine (Cardiology)  
info@sonopath.com

Echocardiogram performed by:

Pamela Harrigan, RDCS  
Pet Animal Ultrasound Service (4paus.com)